

**IUSTI: 2010 European Guideline for the Management of Anogenital Warts in Adults**

C J N Lacey, S C Woodhall, A Wikstrom and J Ross

**Hull York Medical School, University of York, York**

C J N Lacey, S C Woodhall

**Department of Dermatovenereology, Karolinska Hospital, Stockholm, Sweden**

A Wikstrom

**Whittall Street Clinic, Birmingham, UK**

J Ross

Correspondence to: Prof Charles Lacey, Hull York Medical School, University of York, York YO10 5DD, [charles.lacey@hyms.ac.uk](mailto:charles.lacey@hyms.ac.uk)

Keywords: anogenital warts, condylomata acuminata, HPV, guidelines, Europe

## **1. Aetiology and transmission**

Anogenital warts (also known as genital warts, condylomata acuminata, condylomas) are benign proliferative lesions caused by human papillomavirus (HPV) types 6 and 11, which are found in >95% of lesions.<sup>1,2</sup> Anogenital warts are often also co-infected with “high risk” HPVs such as HPV 16.<sup>2</sup> Genital warts are sexually transmitted, with transmission rates of ~60% between partners.<sup>3</sup>

## **2. Clinical features**

### 2.1 Symptoms

Most patients only complain of the presence of the lesions, which are otherwise symptomless. However, symptoms can include itching, bleeding, fissuring or dyspareunia.

### 2.2 Physical signs

Lesions are often found in sites that are traumatised during intercourse and may be solitary, but frequently there will be 5 to 15 lesions of 1–5 mm diameter. Warts may coalesce into larger plaques, and this is more commonly seen with immunosuppression and in diabetes. In uncircumcised men, the preputial cavity (glans penis, coronal sulcus, frenulum, inner aspect of the foreskin) is most commonly affected, while in circumcised men the shaft of the penis is often involved.<sup>4</sup> Warts may also occur at the urethral meatus, pubis, scrotum, groin, perineum, peri-anal area, and anal canal. In females, lesions occur at the fourchette, labia minora, labia majora, pubis, clitoris, urethral meatus, perineum, peri-anal region, anal canal, introitus, vagina, and ectocervix. Intra-anal warts are most common when receptive anal intercourse has been practised, although also occur without such.<sup>5</sup> Warts are very seldom found proximal to the dentate line. Anogenital warts can vary significantly in colour, from pink to salmon red, and from white to greyish white to various shades of brown (pigmented lesions). Warts tend to be non-pigmented, but pigmented lesions are mostly seen on the labia majora, penile shaft, pubis, groin, perineum, and peri-anal area.

## 2.3 Complications

### *Physical and psychosexual implications*

Anogenital warts are frequently perceived as disfiguring and often impact sexual lifestyle. They cause feelings of anxiety, guilt, anger, and loss of self esteem, and create concerns about future fertility and of cancer risk.<sup>6,7</sup>

### *Pre-cancer and cancer*

Both pre-malignant (vulval, anal, and penile intra-epithelial neoplasia, i.e. VIN, AIN, and PIN) or invasive lesions (vulval, anal, and penile cancer) can co-exist within anogenital wart lesions, can develop within existing genital warts, or be misdiagnosed as genital warts. Bowenoid papulosis (BP) are reddish-brown lesions associated with oncogenic HPV types, and are part of the clinical spectrum of anogenital intraepithelial neoplasia. Clinical suspicion of neoplastic change should be aroused by bleeding, abnormal pigmentation, ulceration, or lesions with palpable dermal infiltration. Urgent biopsy or appropriate specialist referral must be considered. Another rare variant of HPV 6/11 disease is the giant condyloma or Buschke-Lowenstein tumour. This is a form of verrucous carcinoma, characterised by aggressive local infiltration into underlying dermal structures. Management requires specialist surgical and oncological referral, with recent reports suggesting good outcomes with chemo-radiotherapy.<sup>8</sup>

## **3. Diagnosis — key points**

- Examine with a good light; a lens or colposcope may be useful for small lesions.
- In men, always check the meatus, and have a low threshold for examining the peri-anal area and performing proctoscopy to examine the anal canal. In women, always check the peri-anal area and perform a speculum examination to exclude cervical or vaginal lesions
- Biopsy is not necessary for typical anogenital warts; biopsy must always be performed if there is any suspicion of pre-cancer or cancer
- Not all papular lesions are caused by HPV. Always consider normal variants such as pearly penile papules and Fordyce spots and differential diagnoses such as

molluscum contagiosum, seborrheic warts, etc.

- HPV typing of anogenital warts does not add information of clinical use, and is not recommended
- Some practitioners use the acetic acid test to diagnose sub-clinical HPV lesions; its place in diagnosis and management remains controversial

#### **4. Management**

In the formulation of these guidelines we have reviewed and considered those produced recently by national groups in the United Kingdom and United States.<sup>9,10</sup> We have also evaluated the evidence that supports our treatment recommendations using grades developed by the Agency for Health Care Policy and Research (see Table 1).<sup>11</sup>

##### 4.1 Information, explanation and advice for the patient

- Patients should be given a detailed explanation of their condition. This should be reinforced by offering them clear and accurate written information. Useful patient oriented resources are available via the CDC <http://www.cdc.gov/std/hpv> and ASHA [http://www.ashastd.org/learn/learn\\_hpv\\_warts.cfm](http://www.ashastd.org/learn/learn_hpv_warts.cfm) websites (IV; C)

##### 4.2 Therapy

###### 4.2.1 Currently available treatments

We carried out a systematic review of randomised controlled trials (RCTs) of treatments for genital warts<sup>12</sup>. Previous systematic reviews and RCTs were identified and the primary data obtained, analysed and collated (see section 6). Some of the results are presented in Table 2. The data confirms that only surgical therapies have primary clearance rates approaching 100%, and that recurrences occur after all therapies. Recurrence rates, including new lesions at previously treated or new sites, are often 20–30% or more. All therapies are associated with local skin reactions including itching, burning, erosions, and pain. Within these caveats, our recommended treatment modalities are:

Home therapy

- Podophyllotoxin (0.15% cream or 0.5% solution)
- Imiquimod (5% cream).

Clinic therapy

- Cryotherapy
- Trichloroacetic acid
- Electrosurgery / scissors excision / curettage / laser

HOME THERAPY

1. *Podophyllotoxin 0.5% solution and 0.15% cream (Ib,A)*

Each course of podophyllotoxin treatment comprises self application twice daily for 3 days, followed by 4 rest days. Use of 0.5% podophyllotoxin solution is convenient for penile warts. However, vulvar and anal warts are more feasibly and efficiently treated with 0.15% podophyllotoxin cream, when inspection, often aided by a mirror and digital palpation, facilitate the application procedure.

Clearance rates of 36–100% after use of 0.5% podophyllotoxin solution for 3-6 weeks have been reported.<sup>13-20</sup> Efficacy with use of podophyllotoxin solution is probably lower in females and circumcised males. Clearance rates of 43-70% have been reported after the use of 0.15% podophyllotoxin cream at 4 weeks.<sup>16-18</sup> Meatal warts and warts on keratinised skin are often refractory.<sup>13</sup>

Up to 65% of patients using podophyllotoxin experience transient and acceptable burning, tenderness, erythema, and/or erosions for a few days when the warts necrotise.<sup>15,16</sup> Recurrence rates of 6-100% have been reported with podophyllotoxin preparations between 8 to 21 weeks after clearance.<sup>13-16,18,19</sup>

Podophyllotoxin is contraindicated during pregnancy, and women of childbearing age must use contraception or abstain from penetrative sexual activity during therapy.

2. *Imiquimod cream 5% (Ib,A)*

Imiquimod cream is supplied as a package of twelve single use sachets. It is applied

to the warts three times a week at bedtime and the area washed with soap and water the next morning. Treatment continues until wart clearance, or for a maximum of 16 weeks. Local reactions at the treatment site may occur and these can be managed by a rest period of several days, or by reducing the frequency of application.

In clinical studies, wart clearance has been reported in 35 - 68% of patients with treatment courses up to sixteen weeks.<sup>21-27</sup> The reported clearance rates are higher in women than in men, and also women have a shorter median time to clearance than men.

Erythema is often seen as a side effect with imiquimod therapy, and sometimes appears to precede clinical resolution. Occasionally severe inflammation is seen necessitating discontinuation of therapy. Phimosis and lichen sclerosis after therapy have also been reported. Relatively low recurrence rates (6-26%) after successful clearance have been reported.<sup>22,23,26,27</sup>

Animal studies with imiquimod have not revealed any teratogenic effects in rats and rabbits. No adverse effects were found on reproduction in a second generation rat study. Two case series of imiquimod use in pregnant women have been published, and no adverse pregnancy outcomes or fetal abnormalities have been reported<sup>28,29</sup>. Nevertheless, more data is needed before imiquimod cream can be considered safe during pregnancy.

## OFFICE THERAPY

### 1. Cryotherapy (Ib,A)

Cryotherapy can be delivered by 'open' (liquid nitrogen) or 'closed' systems. Open application of liquid nitrogen is usually delivered by spray gun device, freezing the lesion and a margin of healthy skin for about 20 seconds. Closed cryoprobe systems utilise circulation of nitrous oxide or carbon dioxide, the probe gently pressed to the surface moistened with saline or lubricating jelly and freezing performed until a freezing "halo" occurs a few millimetres around the lesion. A freeze-thaw-freeze technique is applied to each lesion at each session. Application techniques are difficult to standardise and there may be significant intra-operator differences. Cryotherapy is usually performed at

weekly intervals, although no studies have systematically evaluated different treatment intervals.

Cryotherapy has the advantages of being simple, inexpensive, rarely causes scarring or depigmentation, and is safe in pregnancy. Clinical studies have reported clearance rates in the range of 44–75%,<sup>30-33</sup> and recurrence rates of 21 - 42% one to three months after clearance.<sup>30-32</sup>

## 2. *Trichloroacetic acid (TCA) 80–90% solution (Ib,A)*

TCA is a caustic agent. It is applied sparingly directly to the wart surface with either the wooden or a cotton tip end of an applicator, as per preference, and is usually applied weekly. It is most suitable for small acuminate or papular warts but less easy to use on keratinised or large lesions. TCA is corrosive and overzealous use may cause scarring. A neutralising agent (for example, sodium bicarbonate) should be readily available in case of excess application or spills. When used optimally, a shallow ulcer forms that heals without scarring. Response rates of 56 – 81% have been reported,<sup>31,33</sup> with recurrence rates of 36%.<sup>31</sup> TCA can be used safely during pregnancy

## 3. *Surgical treatment*

A variety of surgical techniques are in use, including electrosurgery, curettage, scissors excision and laser therapy. Surgery may be used as primary therapy, and the majority of patients can be treated under local anaesthesia. Routine use of local anaesthetic cream is recommended before infiltration anaesthesia, reducing discomfort from injections significantly. Use of up to 100 mg lidocaine, as 5 ml of 2% or 10 ml of 1%, for infiltration gives rapid anaesthesia of the epithelium. Adrenaline as adjuvant reduces bleeding but is contraindicated on the penis and in the clitoris region, and clinics therefore may choose not to stock the combined preparations to prevent inadvertent inappropriate use. When performed carefully, simple surgical approaches leave highly satisfactory cosmetic results.

### *(a) Electrosurgery (Ib,A) scissors excision (Ib,A), curettage and laser surgery (IIa,B)*

Modern electrosurgical units utilise alternating current to produce different types of

wave forms resulting in blends of cutting and coagulation. These systems use isolated circuitry, can be monopolar or bipolar, and vary from small simple devices to larger complex systems. Scissors excision is useful when smaller numbers of lesions are present and may be assisted by diathermy to control bleeding and to destroy any conspicuous wart tissue remaining after the excision. Clearance rates of 94-100% and 89-100% have been reported for electrosurgery and scissors excision, respectively, with recurrence rates of 19-29%.<sup>30,34-37</sup>

Curettage is a simple effective technique for small numbers of lesions, and either diathermy or silver nitrate is used for haemostasis. Carbon dioxide laser emissions result in very high power densities being delivered to small tissue volumes. Both electrosurgery and laser surgery should be performed with the use of surgical masks by the treatment team, and the use of a smoke evacuator. We were not able to locate any suitable RCTs evaluating curettage or laser therapy.

(b) *Formal surgery*—Bulky warts, extensive warts, anal / intra-anal warts, and significant lesions in children are most conveniently removed under general anaesthesia by an appropriate surgical specialist.

#### THERAPIES NOT GENERALLY RECOMMENDED

Routine use of podophyllin or interferons is not recommended. Podophyllin 20–25%, a non-standardised resin extract from the *Podophyllum* plant, is inexpensive to produce but is associated with only moderate efficacy. However, podophyllin contains up to 10% of the mutagenic compounds quercetin and kaempferol,<sup>38</sup> and severe systemic toxicity after topical use has been described, including death, intrauterine death, teratogenicity and various neurological complications.<sup>39</sup> In the specialist setting,  $\alpha$ - and  $\beta$ -interferons are sometimes used as adjuvants to surgery in problem cases, and a recent systematic review supported the use of topical or intralesional interferon.<sup>40</sup>

#### 4.2.2 Treatment algorithms

Clinicians who treat patients with genital warts should have access to a range of home

and clinic-based therapies. Choice of therapy depends on the morphology and extent of warts and should be made by mutual agreement between the physician and the patient. Patients with limited disease (1–5 warts) will often opt for immediate therapy in clinic. As warts regress spontaneously in some patients, no treatment is an option for warts at any site. A simple treatment algorithm is illustrated below.

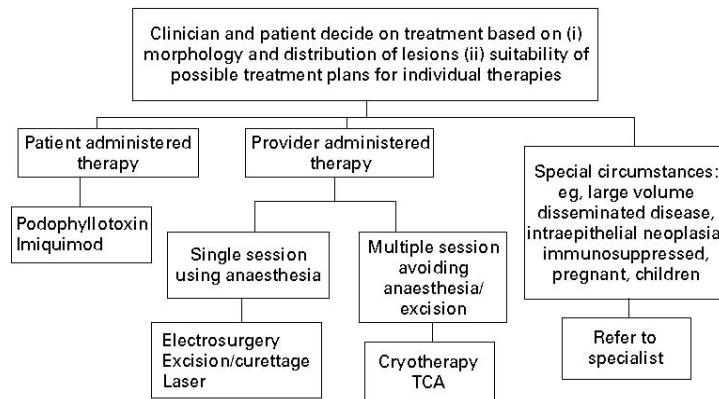


Figure 1. Algorithm for the treatment of external anogenital warts<sup>41</sup>

#### 4.2.3 Treatment in pregnancy

In pregnancy warts may enlarge and multiply. Genital warts present at delivery are associated with a risk of ~ 1 in 400 of the infant developing juvenile laryngeal papillomatosis.<sup>42</sup> There is no proof that treatment diminishes this risk, although reduction of viral burden would seem wise. Liason with the obstetrician in management is recommended.

#### 4.2.4 Treatment in immunocompromised patients

Both HIV infection and iatrogenic immunosuppression are associated with an increased prevalence of anogenital warts. Furthermore, the response to treatment in HIV positive subjects is impaired, and recurrences after treatment are more common.<sup>43,44</sup> Recent studies of the use of imiquimod in patients treated with HAART showed total clearance rates of 31 & 32%,<sup>43,45</sup> whereas an RCT of surgery combined with imiquimod demonstrated a 100% primary clearance.<sup>44</sup>

#### 4.3 Partner notification

- Current partners and, if possible, other partners within the past 6 months, should be assessed for the presence of lesions and for education and counselling about STDs and their prevention
- Condoms have been shown to protect against the acquisition of genital warts<sup>46,47</sup>. Analyses of whether condoms protect against HPV transmission *per se* are more complex with mixed results<sup>47</sup>, but recent data suggests that male condom use may protect females against HPV acquisition<sup>48, 49</sup>. Condom use has also been shown to accelerate disease resolution when both partners have type-concordant HPV infection.<sup>50-52</sup> Therefore condom use is recommended within partnerships when either subject has genital warts until resolution of lesions. (Ib; A)

#### 4.4 Follow Up

- It is good practice for units treating patients with genital warts to develop their own treatment algorithms including local practice and recommendations. Such patient level management protocols should incorporate medical review of cases at least every 4 weeks, with switching of treatments if an inadequate response is observed. Implementation of such treatment algorithms has been shown to result in improved outcomes<sup>53</sup>.

#### 4.5 Prevention / Health Promotion / Vaccination

- Genital warts are commoner in smokers, and smoking behaviour is correlated with sexual behaviour, increased numbers of sexual partners, and adverse reproductive sequelae.<sup>54,55</sup> Although there is no evidence at present that smoking cessation improves the outcome of treatment for genital warts, there is a clear individual and public health rationale for advising smoking cessation. (IV; C)
- Patients with first episode genital warts should be offered sexually transmitted disease screening as per local guidelines. (III, IV; C)
- Female patients should be informed about cervical cytology screening as per local / national guidelines. Recommendations in the UK are that women with genital

warts should be screened according to standard guidelines.

## 5. References

1. Meyer T, Arndt R, Christophers E, Beckmann ER, Schroder S, Gissmann L, et al. Association of rare human papillomavirus types with genital premalignant and malignant lesions. *J Infect Dis* 1998;178:252-5
2. Brown DR, Schroeder JM, Bryan JM, Stoler MH, Fife KH. Detection of multiple human papillomavirus types in condylomata acuminata lesions from otherwise healthy and immunosuppressed patients. *J Clin Microbiol* 1999;37:3316-22
3. Oriel JD. Natural history of genital warts. *Br J Vener Dis* 1971;47:1–13.
4. Cook LS, Koutsky LA, Holmes KK. Clinical presentation of genital warts among circumcised and uncircumcised heterosexual men attending an urban STD clinic. *Genitourin Med* 1993;69:262–4
5. Sonnex C, Schofield JH, Kocjan G, et al. Anal human papillomavirus infection in heterosexuals with genital warts: prevalence and relation with sexual behaviour. *Brit Med J* 1991; 303:1243.
6. Woodhall S, Ramsey T, Cai C, Crouch S, Jit M, Birks Y, Edmunds J, Newton R, Lacey CJ. Estimation of the impact of genital warts on health-related quality of life. *Sex Transm Inf* 2008; 84:161-6
7. Maw RD, Reitano M, Roy M. An international survey of patients with genital warts; perceptions regarding treatment and impact on lifestyle. *Int J STD AIDS*1998;9:571– 8
8. Armstrong N, Foley G, Wilson J, Finan P, Sebag-Montefiore D. Successful treatment of a large Buschke-Lowenstein tumour with chemo-radiotherapy. *Int J STD AIDS* 2009;20:732–4
9. Clinical Effectiveness Group (British Association for Sexual Health and HIV). United Kingdom National guideline for the management of anogenital warts, 2007. <http://www.bashh.org/documents/86/86.pdf>
10. Centers for Disease Control. Sexually Transmitted Diseases Treatment guidelines, 2006. *MMWR* 2006;55:RR-11 <http://www.cdc.gov/std/treatment/2006/rr5511.pdf>
11. US Department of Health and Human Services, Agency for Health Care Policy and Research. Acute pain management: operative or medical procedures and trauma. *ClinicalPracticeGuidelinesNo1*.Rockville, MD: AHCPR. Publication No 92-0023, 1993:107.
12. Woodhall SC, Lacey CJN. Systematic review of treatments for anogenital warts. (in preparation)
13. Von Krogh G, Szpak E, Andersson M, et al. Self-treatment using 0.25%-0.5% podophyllotoxin ethanol solutions against penile condylomata acuminata—a placebo-controlled comparative study. *Genitourin Med* 1994;70:105–9.
14. Beutner KR, Conant MA, Friedman-Kien A. Patient-applied podofilox for treatment of genital warts. *Lancet* 1989;i:831–4.
15. Kirby P, Dunne A, King DH, Corey L. Double-blind randomized clinical trial of self-administered podofilox solution versus vehicle in the treatment of genital warts. *Am J Med* 1990;88:465–70.
16. Claesson U, Lassus A, Happonen H, et al. Topical treatment of venereal warts: a comparative open study of podophyllotoxin cream versus solution. *Int J STD & AIDS* 1996;7:429– 34.
17. Strand A, Brinkeborn R-M, Siboulet A. Topical treatment of genital warts in men, an open study of podophyllotoxin cream compared with solution. *Genitourin Med* 1995;7: 387–90.

18. Lacey CJ, Goodall RL, Tennvall GR, Maw R, Kinghorn GR, Fisk PG *et al.* Randomised controlled trial and economic evaluation of podophyllotoxin solution, podophyllotoxin cream, and podophyllin in the treatment of genital warts. *Sexually Transmitted Infections*.2003;79:270-5.
19. Edwards, A., Atma R, A., and T, R.N. Podophyllotoxin 0.5% v podophyllin 20% to treat penile warts. *Genitourinary Medicine* 1988;64:263-5.
20. Mazurkiewicz W, Jablonska S. Clinical efficacy of Condylone (0.5% podophyllotoxin) solution and cream versus podophyllin in the treatment of external condylomata acuminata. *Journal of Dermatological Treatment* 1990;1:123-5
21. Beutner KR, Tyring SK, Trofatter KF, Jr., Douglas JM, Jr., Spruance S, Owens ML *et al.* Imiquimod, a patient-applied immune-response modifier for treatment of external genital warts. *Antimicrobial Agents & Chemotherapy*.1998;42:789-94
22. Beutner KR, Spruance SL, Hougham AJ, Fox TL, Owens ML, Douglas JM, Jr. Treatment of genital warts with an immune-response modifier (imiquimod). *J Am Acad Dermatol* 1998;.38:230-9
23. Edwards L, Ferenczy A, Eron L, *etal.*Self-administered topical 5% imiquimod cream for external anogenital warts. *Arch Dermatol* 1998;134:25–30
24. Fife KH, Ferenczy A, Douglas JM, Jr., Brown DR, Smith M, Owens ML *et al.* Treatment of external genital warts in men using 5% imiquimod cream applied three times a week, once daily, twice daily, or three times a day. *Sex Transm Dis* 2001;.28:226-31
25. Garland SM, Waddell R, Mindel A, Denham IM, McCloskey JC. An open-label phase II pilot study investigating the optimal duration of imiquimod 5% cream for the treatment of external genital warts in women. *Int J STD & AIDS* 2006;17:448-52
26. Schofer H, Van Ophoven A, Henke U, Lenz T, Eul A. Randomized, comparative trial on the sustained efficacy of topical imiquimod 5% cream versus conventional ablative methods in external anogenital warts. *European Journal of Dermatology* 2006;16:642-8
27. Arican O, Guneri F, Bilgic K, Karaoglu A. Topical imiquimod 5% cream in external anogenital warts: A randomized, double-blind, placebo-controlled study. *Journal of Dermatology* 2004;31:627-31
28. Einarson E, Costei A, Kalra S, Rouleau M, Koren M. The use of topical 5% imiquimod during pregnancy: a case series. *Reprod Toxicol* 2006;21:1-2
29. Audisio T, Roca FC, Piatti C. Topical imiquimod therapy for external anogenital warts in pregnant women. *Int J Gynaecol Obstet* 2008;100:275-6
30. Stone KM, Becker TM, Hagdu A, *et al.*.Treatment of external genital warts: a randomised clinical trial comparing podophyllin, cryotherapy and electrodesiccation. *Genitourin Med* 1990;66:16–19
31. Godley MJ, Bradbeer CS, Gellan M, *et al.* Cryotherapy compared with trichloroacetic acid in treating genital warts. *Genitourin Med* 1987;63:390–2
32. Handley JM, Maw RD, Horner T, Lawther H, McNeill T, Dinsmore WW. Non-specific immunity in patients with primary anogenital warts treated with interferon alpha plus cryotherapy or cryotherapy alone. *Acta Dermato-Venereologica* 1992;72:39-40
33. Sherrard J, Riddell L. Comparison of the effectiveness of commonly used clinic-based treatments for external genital warts. *Int J STD & AIDS* 2007;18:365-8
34. Panici PB, Scambia G, Baiocchi G, Perrone L, Pintus C, Mancuso S. Randomized clinical trial comparing systemic interferon with diathermocoagulation in primary multiple and widespread anogenital condyloma. *Obstet Gynecol* 1989;74:393-7
35. Jensen SL. Comparison of podophyllin application with simple excision in clearance and recurrences of perianal condylomata acuminata. *Lancet* 1985;ii:1146–8
36. Khawaja HT. Treatment of condyloma acuminatum. *Lancet*.1986;i:208-9
37. Khawaja HT. Podophyllin versus scissor excision in the treatment of perianal condylomata acuminata: a prospective study. *Brit J Surg* 1989;76:1067-8

38. Petersen CS, Weismann K. Quercetin and kaempferol; an argument against the use of podophyllin? *Genitourin Med* 1995;71:92–3
39. Lacey CJN. Therapy for genital human papillomavirus-related disease. *J Clin Virol* 2005;32S:S82-90
40. Yang J, Pu Y, Zeng Z, Yu Z, Huang N, Deng Q. Interferons for the treatment of genital warts: a systematic review. *BMC Infectious Diseases* 2009;9:156
41. Von Krogh G, Lacey CJN, Gross G, Barasso R, Schneider A. European Course on HPV associated pathology: guidelines for primary care physicians for the diagnosis and management of anogenital warts. *Sex Transm Inf* 2000;76:162–8
42. Kashima HK, Shah K. Recurrent respiratory papillomatosis: clinical overview and management principles. *Obstet Gynecol Clinics North Am* 1987;14:581–8
43. Cusini M, Salmaso F, Zerboni R, et al. 5% imiquimod cream for external anogenital warts in HIV-infected patients under HAART therapy. *Int J STD AIDS* 2004;15:17-20
44. Viazis M, Vlachogiannakos J, Vasiliadis K, Theodoropoulos I, Saveriadis A, Karamanolis DG. Earlier eradication of intra-anal warts with argon plasma coagulator combined with imiquimod cream compared with argon plasma laser alone: a prospective, randomised trial. *Dis Colon Rectum* 2007;50:2173-9
45. Saiag P, Bauhofer A, Bouscarat F, et al. Imiquimod 5% cream for external genital or perianal warts in human immunodeficiency virus-positive patients treated with highly active antiretroviral therapy: an open-label, noncomparitive study. *Br J Dermatol* 2009;161:904-9
46. Wen LM, Estcourt CS, Simpson JM, Mindel A. Risk factors for the acquisition of warts: are condoms protective? *Sex Transm Inf* 1999;75:312-6
47. Manhart LE, Koutsky LA. Do condoms prevent genital HPV infection, external genital warts, or cervical neoplasia? A meta-analysis. *Sex Transm Dis.* 2002;29:725-35.
48. Winer RL, Hughes JP, Feng Q, O'Reilly S, Kiviat NB, Holmes KK, Koutsky LA. Condom use and the risk of genital human papillomavirus infection in young women. *N Engl J Med.* 2006;354:2645-54
49. Burchell A, Tellier P-P, Coutlee F, Hnaley J, Franco E. Evidence for a protective effect of condoms against male-to-female transmission. 26th International Papillomavirus Conference, Montreal, 2010, Abstract P-622
50. Hogewoning CJ, Bleeker MC, van den Brule AJ, Voorhorst FJ, Snijders PJ, Berkhof J, Westenend PJ, Meijer CJ. Condom use promotes regression of cervical intraepithelial neoplasia and clearance of human papillomavirus: a randomized clinical trial. *Int J Cancer.* 2003;107:811-6
51. Bleeker MC, Hogewoning CJ, Voorhorst FJ, et al. Condom use promotes regression of human papillomavirus-associated penile lesions in male sexual partners of women with cervical intraepithelial neoplasia. *Int J Cancer* 2003;107:804-10
52. Bleeker MC, Berkhof J, Hogewoning CJ, et al. HPV type concordance in sexual couples determines the effect of condoms on regression of flat penile lesions. *Br J Cancer* 2005;92:1388-92
53. Reynolds M, Fraser PA, Lacey CJN. Audits of the treatment of genital warts: closing the feedback loop. *Int J STD & AIDS* 1996;7:347-52
54. Kjaer SK, Tran TN, Sparen P, et al. The burden of genital warts: a study of nearly 70,000 women from the general female population in the 4 Nordic countries. *J Infec Dis* 2007;196:1447-54
55. Hansen BT, Kjaer SK, Munk C, et al. Early smoking initiation, sexual behaviour and reproductive health – a large population-based study of Nordic women. *Prev Med* 2010;51:68-72

## **6. Search strategy**

A scoping search of existing systematic reviews of genital warts treatments was carried out by searching the Cochrane Database of Systematic Reviews, MEDLINE and EMBASE. Searches were carried out in MEDLINE, EMBASE and the Cochrane library (including Cochrane Database of Systematic Reviews, Database of Abstracts of Reviews and Effects and Cochrane Central Register of Controlled Trials) according to a pre-defined search strategy (see Table 3). Randomised controlled trials (RCTs) of provider-administered or prescribed therapies for anogenital warts were eligible for inclusion where participants were 16 years old or over; the warts had been clinically diagnosed and clearance or recurrence rates were reported as an outcome measure. The search was restricted to English-language publications and all databases were searched up to March 2009.

Study selection was a two stage process; abstracts and titles were reviewed and full papers were then obtained for any papers which potentially met the eligibility criteria, at which point the eligibility criteria were applied to the full manuscript. The reference lists of the included papers were hand searched to identify other potentially eligible papers. Due to resource constraints, while the initial electronic search and identification of papers was carried out by two reviewers, the final decision about eligibility was carried out by a single reviewer. Data extraction was carried out using a piloted data extraction template. Data extraction was carried out by one reviewer, with a sample of ~10% of papers being double checked for accuracy by another reviewer. Study quality was determined by applying the Cochrane Collaboration's tool for assessing risk of bias (available from: <http://www.cochrane-handbook.org>).

## **7. Statement of declarations of interest**

Charles Lacey – travel grants to attend conferences from GSK, SPMSD

Jonathan Ross – speakers fees, sponsorship to attend conferences and research grants from Abbott, Boehringer Ingelheim, Gilead, GSK, Roche, BMS, MSD, Bayer and Tibotec

## **8. Composition of Editorial Board**

Keith Radcliffe (Editor-in-Chief), Marita van de Laar, Michel Janier, Jorgen Skov Jensen, Martino Neumann, Raj Patel, Jonathan Ross, Willem van der Meijden, Harald Moi, Jackie Sherrard, Magnus Unemo, Karen Babayan, Angela Robinson, James Bingham, Mikhail Gomberg, Marco Cusini

**Table 1. Levels of evidence and grading of recommendations<sup>11</sup>**

<b>Level</b>	<b>Type of evidence</b>
Ia	Evidence obtained from meta-analysis of randomised controlled trials
Ib	Evidence obtained from at least one randomised controlled trial (RCT)
IIa	Evidence obtained from at least one well designed controlled study without randomisation
IIb	Evidence obtained from at least one other type of well designed quasi-experimental study
III	Evidence obtained from well designed non-experimental descriptive studies, such as comparative studies, correlation studies, and case-control studies
IV	Evidence obtained from expert committee reports or opinions and/or clinical experience of respected authorities
<b>Grade</b>	<b>Recommendation</b>
A (evidence levels Ia, Ib)	Requires at least one RCT as part of a body of literature of overall good quality and consistency addressing the specific recommendation
B (evidence levels IIa, IIb, III)	Requires availability of well conducted clinical studies but no RCTs on the topic of recommendation
C (evidence level IV)	Requires evidence from expert committee reports or opinions and/or clinical experience of respected authorities. Indicates absence of directly applicable studies of good quality

**Table 2: Treatment of anogenital warts among HIV negative patients**

Note that clearance rates and recurrence rates are not directly comparable as clearance was measured at different times from the start of treatment and high loss to follow up was often experienced in the trials.

Treatment / intervention	Treatment schedule	Clearance rates ITT* (range)	Clearance rates PP** (range)	Clearance rates reported at:	Recurrence rates*** (range)	Recurrence rates reported at:
Podophyllotoxin solution 0.5% <sup>13-20</sup>	Twice a day for three days followed by four days break. Two to six weeks treatment.	45% - 83%	55% - 83%	3 to 6 weeks	13% - 100% 13-15,19	8 to 21 weeks from end of treatment
Podophyllotoxin cream 0.15% <sup>16-18</sup>	Twice a day for three days followed by four days break. Maximum four weeks treatment.	43% - 70%	43% - 70%	4 weeks	6% - 55% 16,18	8 to 12 weeks from end of treatment
Imiquimod 5% cream <sup>21-27</sup>	Three times per week.	35% - 68%	55% - 81%	16 weeks	6% - 26% 22,23,26,27	10 weeks to 6 months from end of treatment
Cryotherapy <sup>30-33</sup>	Six to ten weeks of treatment.	44% - 75%	67% - 92%	6 to 10 weeks	21% - 42% 30-33	1 to 3 months from end of treatment
TCA <sup>31,33</sup>	One application per week for a maximum of eight to ten weeks	56% - 81%	81% - 84%	8 to 10 weeks	36% <sup>31</sup>	2 months post treatment
Electrosurgery <sup>30,34</sup>	One to six treatment sessions (median 1)	94% - 100%	94% - 100%	1 to 6 weeks	22% <sup>30</sup>	3 months from end of treatment
Scissors excision <sup>35-37</sup>	One or two excision sessions	89% - 100%	89% - 100%	6 weeks	19% - 29% 35-37	10 to 12 months from baseline

\*All clearance rates are based on conservative estimates of efficacy, where by the intent to treat (ITT) population was included in each case. The number enrolled into each group was taken as the denominator and the number known to have cleared as the numerator. This assumes that for any missing data, participants were assumed not to be cleared.

\*\*Clearance rates based on the non-missing data (per protocol, PP). The number with evaluable follow up data was taken as the denominator and the number known to have cleared as the numerator.

\*\*\*Recurrence rates are based on the recurrences observed among those available for follow up who had originally experienced clearance. Several trials experienced high loss to follow up rates, so recurrence rates should be interpreted with caution.

**Table 3: Search strategy**

<b>Combine with AND search</b>	<b>Population</b> (Combine with OR search)	Keywords: genital wart* anogenital wart* ano-genital wart* ano genital wart* *anal wart* condyloma* venereal wart*	
	<b>Intervention</b> (Combine with OR search)	Plus appropriate mapped/MeSH headings  Keywords: <table style="width: 100%; border: none;"> <tr> <td style="width: 50%;">           podophyllotoxin            podofilox            podophyllin            cryotherapy            liquid nitrogen            imiquimod            aldara            TCA            trichloroacetic acid            BCA            bichloroacetic acid            curettage         </td> <td style="width: 50%; vertical-align: top;">           excision            surgical removal            laser            electrocautery            electrocautery            hyfrecation            ablati*            diathermy            interferon*            5-fluorouracil            polyphenon            photodynamic            *tretin* (to capture acitretin,            tretinoin, isotretinoin)            Retinoids         </td> </tr> </table> Plus appropriate mapped/MeSH headings	podophyllotoxin podofilox podophyllin cryotherapy liquid nitrogen imiquimod aldara TCA trichloroacetic acid BCA bichloroacetic acid curettage
podophyllotoxin podofilox podophyllin cryotherapy liquid nitrogen imiquimod aldara TCA trichloroacetic acid BCA bichloroacetic acid curettage	excision surgical removal laser electrocautery electrocautery hyfrecation ablati* diathermy interferon* 5-fluorouracil polyphenon photodynamic *tretin* (to capture acitretin, tretinoin, isotretinoin) Retinoids		

In addition, filters described in the Cochrane Handbook of Systematic Reviews ([www.cochrane-handbook.org](http://www.cochrane-handbook.org)) were applied to limit the searches to RCTs.